

Volume [13] / 2014
ISSN 2281-3268

FOR Energy Health

International journal
of information and scientific culture

Volume 13

OFFICIAL REVIEW OF **ASACAMPUS**

Treatment of Chronic Craniofacial Pain with Mphi Laser and Orthotic

Bennett C. A.¹, Olmos S. R.²

¹ DMD Tulsa Orofacial Pain & Sleep Disorders Clinic, Tulsa, OK, USA. Board-certified in Craniofacial Pain, Dental Sleep Medicine, and Craniofacial Dental Sleep Medicine.

² DDS, DABCP-CDSM, DABDSM, DAAPM, FIAO, FAAOP, FAACP, FICCMO, FADI Adjunct Professor, University of Tennessee-Memphis, USA.

ABSTRACT

Laser therapy has become an increasingly adopted method of physical medicine to help accelerate healing and reduce pain. Treatment of craniofacial pain using laser therapy has also been vastly researched. The purpose of this study was to determine whether the treatment protocol we use is efficacious in decreasing the painful symptoms of craniofacial pain immediately after treatment. 65 patients (age range 13 to 65) were treated with a dual wavelength NIR laser source. In this Multiwave Loked System (MLS®) laser the two emissions at 808 nm and 905 nm, respectively, with continuous chopped and pulsed delivery, are synchronized. TM joints, masseters, trapezius muscles, and cervical area were treated. The patients were asked to state their overall pain level pre and post treatment using the Visual Analog Scale (VAS). This was then converted into a percentage for ease of documentation. A comparison of pre and post VAS scales showed a 49.9% decrease in pain after the first treatment, 25.2% decrease after the second treatment and 9.0% decrease after the third treatment. In conclusion, the protocol used in the study

provided a clinically relevant decrease in craniofacial pain, and a treatment duration of 8 minutes per session could be adapted to the normal clinical setting.

INTRODUCTION

Laser therapy has become an increasingly adopted method of physical medicine as an adjunct, or as a sole therapy, to treat many diseases. While it has not become mainstream yet, many clinicians are turning to laser therapy as a primary tool of treatment due to its low side effects and also ease of use. There has been extensive research done on the effects and efficacy of Low Level Laser Therapy (LLLT). As of date, over 3,900 articles can be found through PubMed on LLLT and its effectiveness toward treating various pathologies. There are many peripheral benefits to LLLT. Lievens [1] demonstrated that LLLT shortens the time and also improves the quality of tissue repair. This is achieved through an increase of microcirculation in the irradiated area, which in turn improves tissue nutrition while decreasing edema by easing the balance of hydrostatic filtration and absorption pressures. Rochkind [2],

Enwemeka [3], and Efendiev [4] showed that reparation is significantly quicker and quality of tissue reparation is significantly superior when compared to non-irradiated control groups. There have also been many articles, which have shown that LLLT can be effective in treating TMJ pathologies (capsulitis, arthralgia and osteoarthritis) and related craniofacial pain (myalgia and cervicalgia). Bezuur and Hansen [5] showed that 80% of their study population base of 27 patients demonstrated complete resolution of chronic TMJ pain and, to a lesser extent, myofascial pain reduction with consecutive treatment over 5 days. This, however, did not document long-term benefits to the population base. Bradley [6] showed in a larger study that acute jaw pain can be effectively treated with LLLT as a sole therapy, and in more chronic cases, is an effective adjunct therapy to more traditional treatments such as occlusal splints. The study also demonstrated that, for cases of osteoarthritis, laser therapy was almost as effective as intra-articular steroids, without the risks of steroid use. Kim [7] compared the effectiveness of bite splints to laser therapy. Kim showed that in a two and four week span, the laser group showed more significant resolution of symptoms as compared to the bite splint group. However, conventional wisdom states that the bite splint would take longer to become effective. No long-term effects were noted in the study. Lopez [8] demonstrated the effects of dual treatment through the use of bite splints and LLLT. In their study of 168 patients with concurrent treatment through the use of bite splints and LLLT, they showed that, after 10 LLLT treatments, 90% of patients had shown improvement. Temporomandibular joint (TMJ) tomographic x-rays were taken pretreatment and at 6 months in treatment. They demonstrated that the healing had advanced to a stage usually seen after 12 to 18 months of

treatment using a bite splint solely. 88 patients were treated for pain in the jaw muscles, showing a reduction in pain; however, this was temporary, lasting at most 6 hours. The authors concluded that the wavelength used was effective as a complementary method to bite splints, however, it was not optimal for myogenic pain. Conti [9] demonstrated through their double blind study that low doses of LLLT would show statistically significant results for arthrogenous pain, however, the same energy dose in the myogenic group provided very little relief from pain. The conclusion was that higher doses were needed to treat myogenic pain. Sanseverino [10] demonstrated the validity of this conclusion by applying a higher dose to painful points of masticatory muscles. In this study, there was a significant improvement in painful areas with the laser group. In regards to the treatment of acute and chronic TMJ pathologies using LLLT, Salmos-Brito [11] demonstrated that both groups benefitted in terms of pain reduction and maximum mouth opening from the use of LLLT. They found, however, that acute conditions responded more completely to LLLT, in regards to pain reduction and maximum mouth opening, when compared to patients with chronic TMJ pathologies. Pereira [12] showed that both red and infrared laser emissions were successful in reducing facial pain up to 180 days after treatment. However, these treatments were localized to one point per application of therapy and treatment was only applied to points that were tender. Therefore, an extensive palpation exam is needed before each treatment with treatment times varying depending on amount of palpation points that are tender. Again, a specific clinically relevant protocol to treat patients was not well established. Likewise, Ahrari [13] showed in a double blind study that treating myogenous TMD decreased pain and increased function. This study, however,

was again limited as the treatment time was 3 sessions over a 4 week period, and palpation of many points was done at each visit to determine the areas to be treated. This length of treatment does not show great clinical relevance as it would be impractical in the clinical setting.

The problems with most LLLT studies of TMJ pathologies and related craniofacial pain are two-fold. First, the treatment time per visit is extensive and includes many treatments. This approach does not lend itself toward effective clinical use of LLLT for the average clinician, as it takes a lot of doctor and patient time. Secondly, most of the previous studies have focused primarily on the TMJ and masticatory muscle pain, while excluding other related myalgias.

There is also an ongoing debate as to what wavelength is most effective in treating pain. Ortutay [14] compared 13 different wavelengths (604-1219 nm) and showed that as long as dosage was controlled, the same pain alleviation was achieved regardless of wavelength. However, his study focused solely on lasers that emitted only one wavelength.

As of date, there are no established protocols for LLLT treatment of TMJ capsulitis, arthralgia, osteoarthritis and resultant other myalgias, especially in terms of an effective protocol to be used in a clinical setting. The purpose of this study was to determine whether the protocol we used for the treatment of patients suffering from TMJ capsulitis, arthralgia and/or facial myalgia produced an immediate relief of painful symptoms in the patient.

MATERIALS AND METHODS

The study group consisted of 35 women with mean age of 41.5 (+13.6) with a range from 13-65 years of age. Patients were collected from 2 independent clinical

sites, in San Diego CA and St. Charles, IL. However, the protocols for laser treatment were identical. All patients complained of symptoms of TMJ pain, masseter pain, cervical pain, and/or shoulder pain. They had been previously diagnosed with TMJ pathologies ranging from capsulitis to osteoarthritis. The exam consisted of using muscle palpation, clinical exam, Joint Vibration Analysis (JVA) and Cone Beam Computed Tomography (CBCT) or Tomograms. All patients were being concurrently treated with functional orthotics as they were in active therapy for their varying TMJ pathologies. The types of orthotics used were a mandibular positioned day appliance for waking hours and a maxillary positioned night appliance for sleep. The positions were taken at the minimum speaking space using the phonetic "S" technique during the day orthotic and the maximum speaking space using the same phonetic "S" technique for the night orthotic, as described by Singh [15].

The laser therapy was administered by using a Multiwave Locked System (MLS®) laser (model Mphi, ASAlaser, Vicenza, Italy) which is significantly different than other laser delivery systems: it combines and synchronizes a pulsed emission at 905 nm and a continuous chopped emission at 808 nm wavelength.

MLS® laser therapy was applied with the following protocols:

- Cervical region- 1 minute at an intensity of 50% and a frequency of 700 Hz. Continuous vertical movement was performed from the base of the skull to the start of the upper back. Total of 16.4 J applied (Figure 1).
- Upper Trapezius region- 1 minute 30 seconds at an intensity of 50% and a frequency of 700 Hz. Continuous horizontal movement was performed from the spine at the base of the

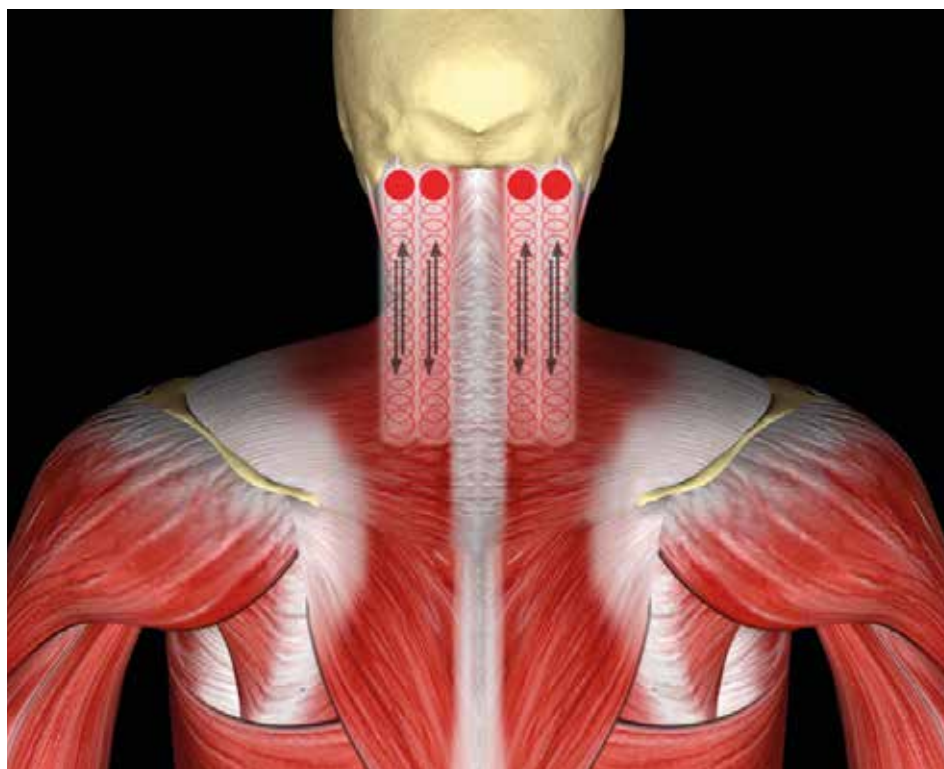


Figure 1

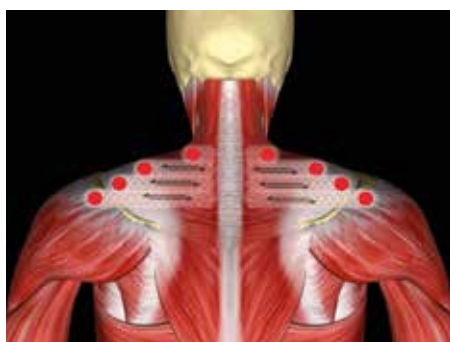

Figure 2

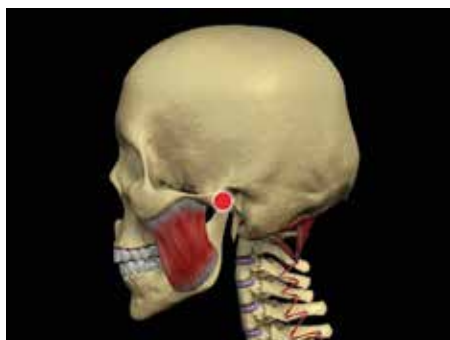

Figure 3

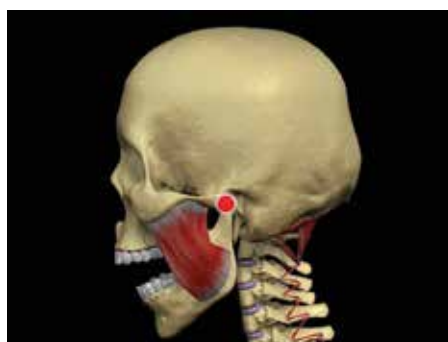

Figure 4

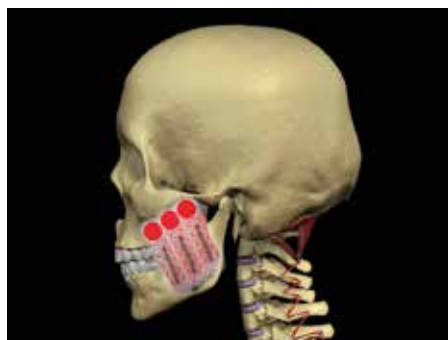

Figure 5

cervical region to the acromion. Total of 24.6 J applied (Figure 2).

- TMJ Lateral Capsule - 30 seconds at an intensity of 50% and a frequency of 350 Hz. Continuous circular movements around the lateral pole of the TM joint. Total of 7.7 J applied (Figure 3).
- TMJ Posterior Joint Space - 30 seconds at an intensity of 50% and a frequency of 350 Hz. The patient rested their incisors on a bite block and the laser was continuously moved in circles around the posterior TM joint space. Total of 7.7 J applied (Figure 4).
- Masseter muscles - 30 seconds at an intensity of 50% and a frequency of 350 Hz. Continuous vertical movements were made along the path of the masseter muscles. Total of 7.7 J applied (Figure 5).

RESULTS

The reductions in pain were cumulative; therefore, the second treatment reduction was applied to the residual pain after the first treatment and the third treatment reduction was applied to the residual pain after the first and second treatment. When evaluating the percent reduction of painful symptoms after conversion from before and after VAS scores, it was noted that the percent reduction in pain after the initial treatment was 49.9% while the percent reduction in pain following the second treatment was 25.2% and the percent reduction in pain following the 3rd treatment was 9.0%. The non-parametric Wilcoxon Rank-Sum Test was applied to the data due to its non-normality (See Table I).

The Wilcoxon Rank - Sum Test showed a significant reduction from the first to second application ($p < 0.001$) and a smaller, yet still statistically very relevant reduction from the second to the third application ($p < 0.01$). This suggests a process of diminishing returns through subsequent treatments, however, it also shows that a variable number of treatments is justified.

Reduction of Discomfort	After 1 st Tx Residual	After 2 nd Tx Residual	After 3 rd Tx Residual
mean	49.9%	25.2%	9.0%
Confidence Interval	43.3 - 57.5	18.2 - 32.2	2.8 - 15.2
Std Dev	23.06	21.22	18.65
Wilcoxon Rank p <		1 st to 2 nd 0.001	2 nd to 3 rd 0.01

Table I

It should be noted that 12 patients stated upon the follow-up appointment that they continued to experience a decrease in pain for about 2 hours after treatment. However, this decrease in pain was not an object of the study and therefore was not considered in the analysis.

One patient experienced slight dizziness within the first hour after laser treatment was accomplished. No other side effects were noted following treatment. None of the patients stated that she did not feel some relief from the treatment.

DISCUSSION

For many years LLLT has been widely used to treat joint and muscle diseases of different origins. The MLS[®] laser was chosen as laser source because it combines two different infrared emissions at wavelengths of 808 and 905 nm, respectively. The 808 nm radiation is absorbed by the cytochrome oxidase and it is known that the consequent enzyme activation promotes the production of ATP [16]. It has been demonstrated on animal models that exposure to 905 nm radiation significantly increases the activity of complexes I, II, III, IV of the respiratory chain and succinate dehydrogenase, thus leading to the synthesis of ATP [17]. In summary, both the emissions of the MLS[®] laser favor the production of ATP, acting synergistically on the main biochemical pathways of cellular energy metabolism. ATP availability is necessary for all the

biological functions, but particularly important for muscle homeostasis that needs to be restored in TMD.

Moreover, recent results of in vitro studies demonstrated that MLS[®] laser favors muscle cell maturation, enhances phosphatase activity, increases the production of the NLRP10 protein, which exerts significant anti-inflammatory activity through inhibition of conversion from pro-interleukin-1 β to interleukin-1 β , one of the most important mediators of inflammation [18].

Along with using the MLS[®] laser, the specific protocol was both clinically applicable and successful in decreasing the VAS and resultant pain of the patient. While most studies have concentrated only on treating myofascial points, the correlation between jaw/facial musculature inflammation and neck/shoulder pain have also been established. This is the result of forward head posture associated with TMJ capsulitis. Olmos [19] showed that patients with TMJ capsulitis presented with forward head posture and that after treatment and a reduction of inflammation, the statistical analysis showed a return of 4.43 inches of a more normal, more erect head posture. If the neck and shoulder muscles are involved in TMJ pathology, then it stands to reason that they should also be included in treatment for the patient to receive maximum benefits. Simmons [20] found occipital cephalgia is a

primary symptom of TMJ inflammation occurring on average 94% of the time at the insertion of the extensor muscles of the neck and shoulders, right at their insertions to the occiput.

There were certain limitations to this study. Due to the study being done entirely in a private practice setting, there was no placebo group and treatment with the laser was done concurrently with orthotic treatment to decompress the TM joints. The size of the sample group was also smaller, although large enough to achieve statistical significance. Finally, due to the typical prevalence of females to seek treatment for TMJ pathologies, this group was also entirely female. A follow up study is indicated with a larger sample size, more diverse sample group, along with a blinded placebo added.

Based on the results of the study, the protocol described has been shown to be an effective treatment to aid in the reduction of craniofacial pain. The success of the therapy results from anti-inflammatory and analgesic properties of the 808 nm and 905 nm emissions of the laser. The 12 subjects, that found a resulting decrease in pain in the hours, after treatment benefited of the anti-inflammatory action

CONCLUSION

This study demonstrates that MLS[®] therapy can be an effective supplement to the clinical setting. While many studies

have shown LLLT to be effective, many have used protocols that were not clinically relevant, such as extended treatment time or treatment for many consecutive days. In the typical clinical setting, long treatment times are impractical. Thus the 8 minute treatment time, in conjunction with showing an immediate reduction in painful symptoms, demonstrates that the protocol can be implemented into a clinical practice.

REFERENCES

- Lievens PC, Delforge AL. Efficiency of infrared laser treatment examined in the healing of bedsores. *Clin Laser Mon.* 1992, Oct;10(10):159-60.
- Rochkind S, Geuna S, Shainberg A. Chapter 25: Phototherapy in peripheral nerve injury: effects on muscle preservation and nerve regeneration. *Int Rev Neurobiol.* 2009, 87:445-64.
- Enwemeka CS, Parker JC, Dowdy DS, Harkness EE, Sanford LE, Woodruff LD. The efficacy of low-power lasers in tissue repair and pain control: a meta-analysis study. *Photome Laser Surg.*, 2004, Aug;22(4):323-9.
- Efendiev AI, Sarosek IuK, Dadashev AI. Laser radiation in the infrared range in the treatment of aseptic postoperative wounds. *Vestn Khir Im.*, 1992, Mar;148(3):291-3.
- Bezuur NJ, Hansson TL. The effect of therapeutic laser treatment in patient craniomandibular disorders. *J Cranomandib Disorders.*, 1988, 2: 83-86.
- Bradley PF, Reblini Z. Low intensity laser therapy (LILT) for temporomandibular joint pain: a clinical electromyographic and thermographic study. *Laser Therapy.*, 1996, 8 (1): 47.
- Kim Ki-Suk, Kim Young-Ku. Comparative study of the clinical effects of splint, laser acupuncture and laser therapy for temporomandibular disorders. *J Dental College, Seoul Nat Univ.*, 1988, 1 (12):195.
- Lopez VJ. El laser en el tratamiento de las disfunciones de ATM. *Revista de Actualidad de Odontoesomatologica Espanola.* 1986; (Jun): 35.
- Conti PC. Low level laser therapy in the treatment of temporomandibular disorders (TMD): a double-blind pilot study. *Cranio.*, 1997, 15 (2): 144-149.
- Sanseverino NTM, Sanseverino CAM, Ribeiro MS et al. Clinical evaluation of the low intensity laser antialgic action of GaAlAs (785 nm) in the treatment of the temporomandibular disorders. *Laser Med Surg Supplement*, 2002, 14:18.
- Salmos-Brita JA, de Menezes RF, Teixeira CE, Gonzaga RK, Rodrigues BH, Braz R, Bessa-Nogueira RV, Gerbi ME. Evaluation of low-level laser therapy in patients with acute and chronic temporomandibular disorders. *Lasers Med Sci.* 2013, Jan;28(1):57-64.
- Pereira TS, Flecha OD, Guimaraes RC, de Oliveira D, Botelho AM. Efficacy of red and infrared lasers in the treatment of temporomandibular disorders—a double-blind, randomized, parallel clinical trial. *Cranio.*, 2014, Jan; 32 (1):51-6.
- Ahrari F, Madani AS, Ghafouri ZS, Tuner J. The efficacy of low-level laser therapy for the treatment of myogenous temporomandibular joint disorder. *Laser Med Sci.* 2014, Mar;29(2):551-7.
- Ortutay J, Barabas K, Mester A. Laser therapy in rheumatology. *Cochrane Database Syst Rev.* 2000;(2):CD002049.
- Singh GD, Olmos SR. Use of a sibilant phoneme registration protocol to prevent upper airway collapse in patients with TMD. *Sleep Breath.*, 2007, Dec;11(4):209-216.
- Oron U, Illic S, De Taboada L, Streeter J. Ga-As (808 nm) laser irradiation enhances ATP production in human neuronal cells in culture. *Photomed Laser Surg.* 2007, 25(3):180-2.
- Silveira PC, Silva LA, Fraga DB, Freitas TP, Streck EL, Pinho R. Evaluation of mitochondrial respiratory chain activity in muscle healing by low-level laser therapy. *J Photochem Photobiol B*, 2009, 95(2):89-92.
- Monici M, Cialdai F, Ranaldi F, Paoli P, Boscaro F, Moneti G, Caselli A. Effect of IR laser on myoblasts: a proteomic study. *Mol. BioSyst.*, 2013, 9, 1147-1161.
- Olmos SR, Kritz-Silverstein D, Halligan W. The Effect of Condyle Fossa Relationship on Head Posture. *J Craniomandib Practice.*, 2005, 1:48-52.
- Simmons HC. Anterior Repositioning Appliance Therapy for TMJ Disorders: Specific Symptoms Relieved and Relationship to Disk Status on MRI. *J Cranio Practice.*, 2005.